

PATIENT

Hudson Heinsimer

SPECIES

Canine

BREED

Chihuahua/Dachshund

SEX

Male Neutered

AGE

9 years

WEIGHT

16lbs

INTERPRETED BY

Maggie Machen Lamy,
DVM, DACVIM
(Cardiology)

IMAGING PERFORMED BY

Kelly Vazquez, CVT

HOSPITAL NAME

Animal General on
Hudson

REFERRING VET

Dr. Tierney

INVOICE

20626

DATE

8/18/21

PRESENTING CLINICAL SIGNS

History: Recheck echo. Grade 3 murmur, owner wanting a dental.
-Pertinent previous echo findings (2/2020 MML): Mild MR, normal dimensions/function.

ECHOCARDIOGRAM FINDINGS

2D, m-mode, color flow and doppler imaging is available. Diffuse thickening of mitral valve leaflets with no obvious prolapse into the left atrial lumen. Moderate eccentric mitral regurgitation with normal left atrial dimension. Normal LV diameter with adequate myocardial function. The tricuspid valve appears normal with no tricuspid regurgitation. Normal right atrial and ventricular diameter and morphology indicating no overt evidence of pulmonary arterial hypertension. The pulmonic and aortic valves are normal in morphology and mobility. Normal aortic outflow velocities with laminar flow. No obvious aortic insufficiency. No pericardial or pleural effusion noted. No obvious cardiac masses.

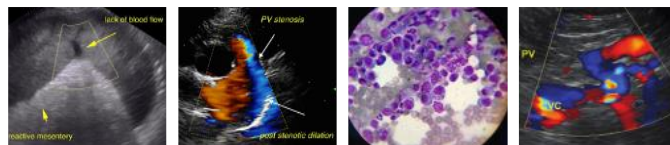
CARDIAC CHART

CANINE CARDIAC PARAMETERS	MR VMAX (m/s)	TR VMAX (m/s)	LA/AO (Boon method)	LA/AO (Heart Base; Swe)	FS (%)	EF (%)	EPSS (cm)
NORMAL PARAMETER	4.5-5.5	<2.7	1.3	<1.6	28-40	40-100	<0.6
PATIENT	5.0	NA	1.2	1.1	40	72	NM
CANINE CARDIAC PARAMETERS	HR (BPM)	AV VMAX (m/s)	PV MAX (m/s)	BODY WEIGHT (kg)	LA 2D short axis Base view (cm)	LVIDd Avg; 2D and m-mode short axis (cm)	LVIDs Avg; 2D and m-mode short axis (cm)
NORMAL PARAMETER	50-100	0.7-1.7	0.7-1.6	BELOW	BELOW	BELOW	BELOW
PATIENT	120	1.4	1.0	7.3	1.3	2.7	1.6
*Normal chamber parameters expressed as a mean value (SD)				3	1.27 (5.3)	2.46 (2.46)	1.36 (5.5)
BODY WEIGHT DEPENDENT PARAMETERS				5	1.40 (4.5)	2.74 (5.2)	1.60 (4.7)
*Note: All measurements based upon multi-modal images and methods. An average value is reported.				10	1.50 (3.8)	3.27 (3.5)	2.06 (3.1)
				15	1.83 (2.0)	3.71 (2.4)	2.43 (2.1)
				20	2.02 (1.9)	4.14 (2.2)	2.80 (2.0)
				25	2.18 (2.4)	4.48 (2.9)	3.10 (2.5)
				30	2.33 (3.3)	4.83 (3.9)	3.39 (3.4)
				35	2.48 (4.3)	5.17 (5.0)	3.69 (4.5)
				40	2.62 (5.2)	5.48 (6.1)	3.96 (5.4)
				50	2.88 (7.1)	6.07 (8.3)	4.46 (7.4)

INTERPRETATION OF THE FINDINGS & FURTHER RECOMMENDATIONS

Chronic degenerative valve disease persists without evidence of significant progression. While the quantitative MR is increased, the overall left heart is similar to the prior study. This would indicate the disease is well compensated for and no concurrent issues are noted.

Unchanged stage B1 disease indicates slow progression overall. Continued assessment of progression is recommended in the future; however, at this stage the risk remains low for



PATIENT

Hudson Heinsimer

complication. Monitor for development of a cough, labored breathing, exercise intolerance or collapse episodes.

SPECIES

Canine

No cardiac contraindication for general anesthesia prior to cardiac chamber enlargement.

BREED

Chihuahua/Dachshund

Recommend conservative monitoring with a recheck echocardiogram in 6-12 months, sooner if any development of clinical signs.

SEX

Male Neutered

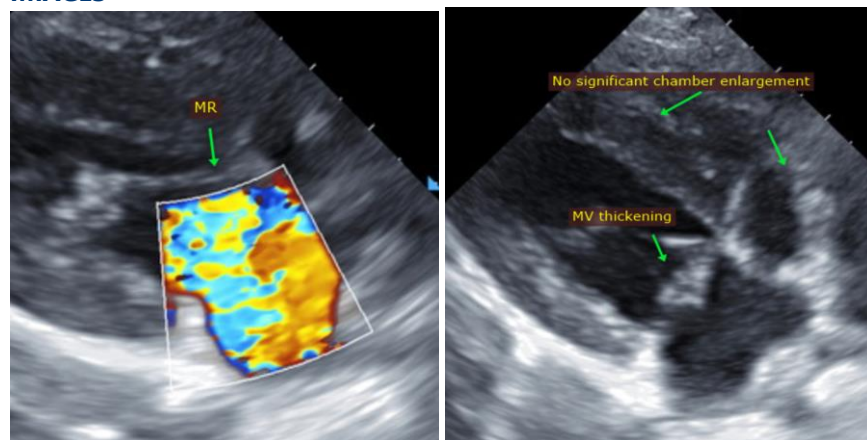
AGE

9 years

WEIGHT

16lbs

IMAGES



INTERPRETED BY

Maggie Machen Lamy,
DVM, DACVIM
(Cardiology)

The information and recommendations provided are based on the images presented by the referring veterinarian. No evaluation can be communicated regarding pathology that was not visible in the image/video clips provided.

IMAGING PERFORMED BY

Kelly Vazquez, CVT

Thank you for this referral. This report was generated using transcription software, and minor dictation errors may be present. If the clinical or image interpretation does not parallel your findings or if I can be of any further assistance, please contact me.

HOSPITAL NAME

Animal General on Hudson

Maggie Machen Lamy, DVM
Diplomate of the American College of Veterinary Internal Medicine (Cardiology)
info@sonopath.com

REFERRING VET

Dr. Tierney

INVOICE

20626

DATE

8/18/21